



UPPER CERVICAL ORTHOGONAL - COWIN

Information, patient testimonials and copyright permission provided by Robert Cowin, D.C. and Kathleen Bras, D.C. (retired); Cowin Chiropractic Clinic, 306 Crown Street, Wollongong, NSW 2250 AUSTRALIA Ph. IDD +61 2 4228 8922

Email: robcowin@ozemail.com.au

UPPER CERVICAL ORTHOGONAL CHIROPRACTIC APPROACH

The Cowin & Bras approach to chiropractic is known as Upper Cervical Orthogonal and employs a gentle, full-console (i.e. not hand-held) minimal-force (three pounds) adjusting instrument.

Our methods were observed by Wollongong University mathematicians Aldis and Hill and written up in the Journal and Proceedings of the Royal Society of NSW in 1979.^[1] Before chiropractic care begins, specialised X-rays are taken on our premises.^{[2][3][4][5][6][7]}

UPPER CERVICAL ANALYSIS: Our procedures are based on the traditional chiropractic concept of vertebral subluxation (vertebral misalignment causing neurological insult).^[8]

Most patients who first attend our office do so because they have been unable to find help for their problems for a long time — on average 6.1 years [1999 Survey of Practice].

The following pictures and text are examples of procedures employed on the patient who was the subject of an article by **Cowin R and Bryner P**, that is “**Hearing Loss, Otalgia and Neck Pain: A Case Report on Long-Term Chiropractic Care That Helped to Improve Quality of Life. Chiropr J Aust 2002 Dec; 32(4):119-30.**”

FIGURE 1: Placement of radio-opaque artifacts on radiolucent surface-anatomy structures prior to taking upper-cervical x-rays.

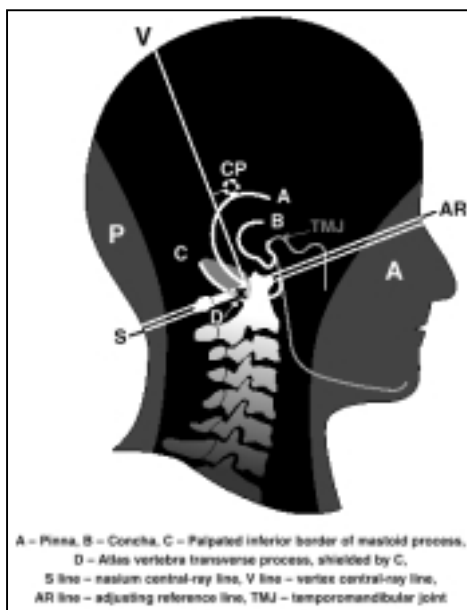
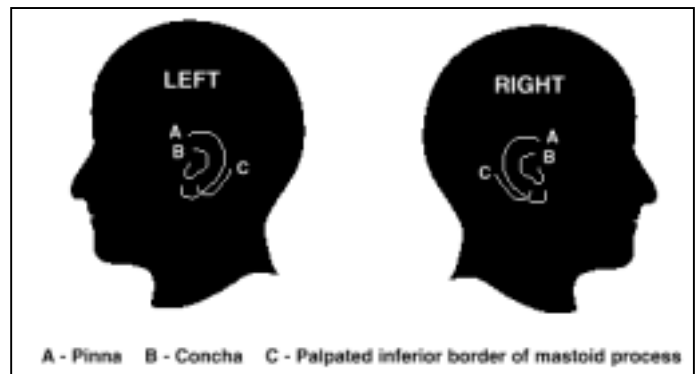


FIGURE 2: Diagram of subject’s natural lateral (sagittal-plane) x-ray, showing wire artifacts on surface-anatomy structures (see previous figure) and soft-tissue filters on the anterior & posterior aspects of the subject’s head & neck (shaded sections A & P). Right side structures only are illustrated.

The lateral x-ray was the first of three initial (“pre”) films exposed and was developed and used as a pilot film to indicate the direction of the central ray for the nasium (S-line) and for the vertex (V-line) exposures.

Later, it was also used to help identify relations between the atlas transverse processes and neighbouring structures in locating the target and trajectory for the adjustive force.

FIGURE 3: Diagram of subject's "pre" nasium (anterior to posterior, frontal plane) x-ray.

Note the relationships of atlas transverse processes (C1TP) to the mastoid processes, as indicated by the bimastoid line (BL) and the palpated bimastoid line (PBL).

The chiropractors were unable to find a satisfactory adjustment contact point (CP) at or near the right C1TP from which to deliver either a hand or instrument adjustment.

They therefore selected adjustment vectors of R48 A12, a percussion instrument adjustive force and trajectory from a CP on the squamous portion of the right temporal bone to the right C1TP.

The trajectory is indicated by dotted line to CP.

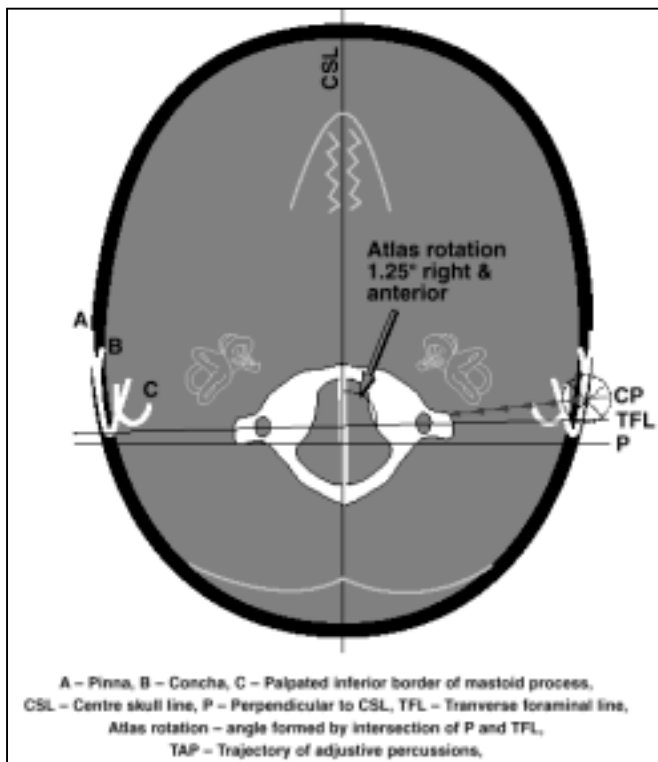
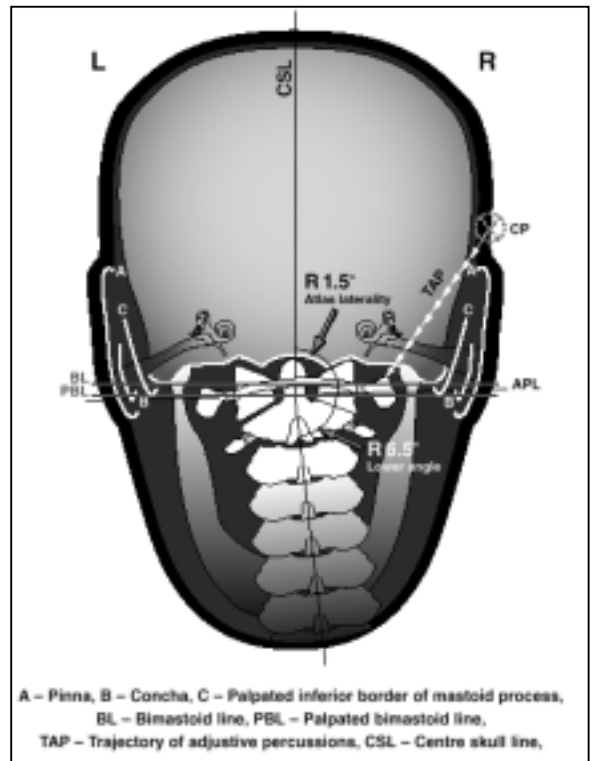


FIGURE 4: Diagram of subject's "pre" vertex plane) x-ray.

A surprising number of stubborn health problems have been helped by chiropractic care over the past 106 years. Current conjectures for the successes reported in the past century include the following component ideas. Most persistent health problems have more than one cause.

A frequent contributing cause is somatic disturbance, such as loading distortion on the supporting structures, causing the highly movable spinal bones to lose their proper alignment.

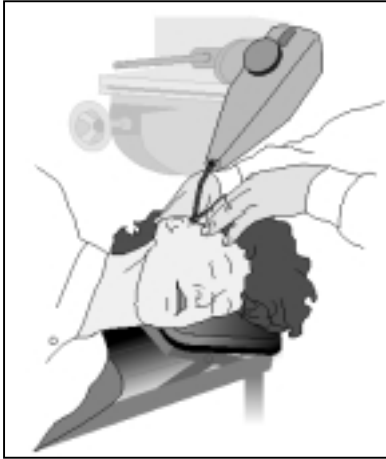The somatic disturbance most frequently assessed and treated by chiropractors, called a subluxation, is a persistent and/or recurring, small alteration in alignment, movement integrity and/or physiological function in one or more spinal motion segments.^[9]

SOMATIC DISTURBANCES ARE OFTEN OVERLOOKED AND/OR POORLY ASSESSED IN PATIENTS WITH PERSISTENT ILLNESS.

ADJUSTING BY HAND AND BY INSTRUMENT.

By hand: A wide spectrum of manual forces and techniques is found in the chiropractic profession. Recent studies have reported that they are safe and effective.^{[10] [11]} They are also generally reported as pain-free and often may be in the order of 24 pounds.^[12] Most hand-adjusting chiropractors are very gentle and highly skilled.

By instrument: The adjustive force can be very precisely directed and needs very little force. An instrument set at three pounds delivers the adjustive force from the instrument used in this office. This force is so light that many patients report that they cannot feel it being done.



The diagram is of the upper-cervical vertebral adjustment showing the fixed stylus of percussion cervical adjusting instrument in position and compressing the skin over the subject's temporal bone contact point (CP) to a depth of about 2mm.

The instrument delivers mechanical impulses of approximately 13N force to the stylus, producing a volley of small shake waves. A part of each shake wave is transmitted to the atlas transverse process.

Source: Instrument picture; Chiropractic Journal of Australia; Vol. 32; No. 4; Dec 2002; Pg: 122, Fig. 1.

[Finally, and also in our opinion, when you need a chiropractic adjustment, nothing else will do!](#)

Robert Cowin, D.C. and Kathleen Bras, D.C. (retired)

References:

1. Aldis OK, Hill JM. Analysis of a chiropractor's data. (Reprinted by permission from the Authors and the Royal Society of New South Wales, Journal and Proceedings 1979; 112:93-9). J Aust Chiropractor's Assoc 1981; 12(1):8-14.
2. Owens LF. Line drawing analyses of static cervical X-ray used in chiropractic. J Manipulative Physiol Ther 1992; 15(7):442-49.
3. Sigler DC, Howe JW. Inter- and intra-examiner reliability of the upper cervical x-ray marking system. J Manipulative Physiol Ther 1985; 8:75-80.
4. Jackson BL, Barker W, Bentz J, Gambale AG. Inter- and intra-examiner reliability of the upper cervical X-ray marking system: A second look. J Manipulative Physiol Ther 1987; 10:157-63.
5. Keating JC, Boline PD. The precision and reliability of an upper cervical X-ray marking system: lessons from the literature. Chiro J Chiro Res Study Clin Invest 1988; 1:43-9.
6. Sigler & Howe, Jackson & Barker. Letters to the Editor. J Manipulative Physiol Ther 1988; 11(3):228-230.
7. Rochester RP. Inter- and intra-examiner reliability of the upper cervical X-ray marking system: A third and expanded look. Chiropr Research J 1994; 3(1):23-31.
8. Rosner AL. The Role of Subluxation in Chiropractic. 1997 Monograph. FCER (Foundation of Chiropractic Education and Research). Des Moines.
9. Chance MA, Peters RE. What's in a name? Editorial. Chiropr J Australia 1994 Sep; 24(3):81.
10. Haldeman S, Kohlbeck FJ, McGregor M. Risk factors and precipitating neck movements causing vertebral artery dissection after cervical trauma and spinal manipulation. Spine 1999; 24(8):785-94.
11. Chapman-Smith D. The chiropractic profession. The Chiropr Report 1997 March; 11(2): 1-8.
12. Kawchuk GN, Herzog W, Hasler EM. Forces generated during spinal manipulative therapy of the cervical spine: a pilot study. J Manipulative Physiol Ther 1992; 15:275-8.

CHIROPRACTIC FOR HEARING LOSS, EARACHE AND NECK PAIN - A CASE

REPORT

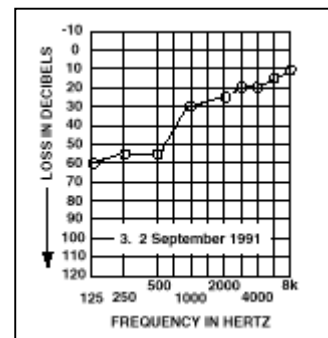
**Cowin R, Bryner P (2002) *Hearing Loss, Otagia and Neck Pain: A Case Report on Long-Term Chiropractic Care that Helped to Improve Quality of Life*, Chiro J Aust, 32(4):119-130 (Appendix D)

Source: This extract from "Chiropractic Information Manual" – Chiropractor's Association of Australia; February 2003, Vol. 03/1 – David Chapman-Smith LL.B. (Hons) FICC (Hons) www.chiropracticreport.com

"There is still sparse scientific literature on the connection between neck and ear problems. There has never been a case study of long-term chiropractic management of a patient with severe ear problems, including Meniere's Disease (hearing loss, tinnitus and vertigo resulting from non-suppurative disease of the labyrinth with distension of the membranous labyrinth).

1. Here is just such a study from Cowin and Bryner (above) in Australia which is important because:
 - a. It is of excellent quality, and can be shown to anyone in the scientific and healthcare communities with confidence.
 - b. It demonstrates thorough clinical records including the use of an audiologist for interdisciplinary assessment, and the importance of using precisely the correct specific chiropractic adjustment technique.
 - c. It reports a continuous association over 7 years between:
 - i. Recurrences of neck pain and ear symptoms
 - ii. Relief of symptoms and chiropractic adjustment
 - d. It also reports an excellent clinical result for a patient whose life was devastated by her ear problems, received no substantial assistance elsewhere, but was able to resume all-important aspects of her life under chiropractic management.

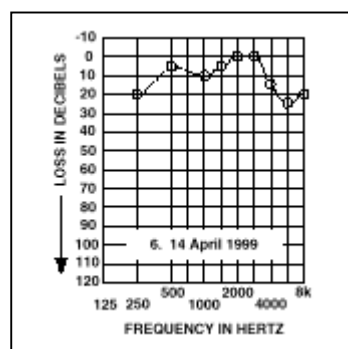
2. See the paper for full details, but key points include:
 - a. A woman schoolteacher, injured in a head-on collision in a motor vehicle accident in 1978, experienced severe radiating right-sided head and neck pain. Daily medication for six months was ineffective. She then got significant relief under chiropractic care through to 1991. However she had various recurrences of pain for which she would visit a chiropractor approximately 6 or 7 times a year during severe episodes. [121/1].
 - b. From 1991 she began to experience ear symptoms and "the ear was at its worst when the neck pain was at its worst." During the next 32 months she complained of these symptoms to 10 health professionals and commenced taking diuretic medications, but her symptoms of severe otalgia (earache), hearing difficulty, tinnitus (ringing or other noises in the ear) and dizziness got progressively worse to the point where they dominated her life. She



was unable to perform many household chores, to participate in sports and social life, and began retraining in sign language to teach hearing-impaired students because she couldn't handle the noise of regular teaching.

- c. In October 1993, at the age of 43, she sought chiropractic care from Dr. Cowin and his partner. The present case report covers 7 years of care from that point through to October 2000.
- d. Her medical diagnosis was Meniere's Disease. Her chiropractic diagnosis was "right anterior 'into-the-angles' upper cervical vertebral subluxation" [121/2/bottom].
- e. She was treated with a modified Pettibon adjusting device as described and illustrated, and was also given a semi-cylindrical neck support ("Chinese Pillow") [122/1/1 and Figure1].

- f. Results were that the patient had no tinnitus or otalgia for four days after the first adjustment and through to the next visit. Over the full 7 years she received 180 adjustment visits (an average of 25.7 per annum, but initially twice weekly, then twice monthly, then after 5 months on such frequency as the patient felt necessary, having regard to her condition which she was monitoring closely), with an average of 46 days relief per treatment. On two occasions treatment aggravated symptoms - obviously disappointing, but perhaps further evidence of the causal relationship between the spinal condition and the ear problems. Her diary entries show progressive improvement [124/2/bottom], and throughout the 7 years of chiropractic management she continued fulltime teaching. She also resumed her household chores and social life, studied successfully for a master's degree in education, and discontinued her diuretic medication [126/1/bottom].



- g. Apart from the patient's diary entries, her improvement was closely monitored with good clinical records and objectively documented through audiology, radiology, range of motion and leg length inequality tests. [126/1].

- 3. As Cowin and Bryner note, "this case illustrates, over a longer period than found in previous reports, that non-musculoskeletal symptoms such as those associated with Meniere's Disease can change quickly following chiropractic adjustment." [126/2/1].

They also note that this case indicates that for some patients and some problems you need more than "a less discriminating-mobilizing force that simply makes the joints easier to move." What may be important is delivery of the "correct vector". In the case of the technique used with this patient, the correct vector was "the careful determination of alignment of the atlas relative to surrounding tissues." [127/1/3]. Note that this patient had had various earlier physical interventions - acupuncture, massage, Feldenkrais, yoga and different chiropractic care - without prolonged success. [126/2/bottom]."